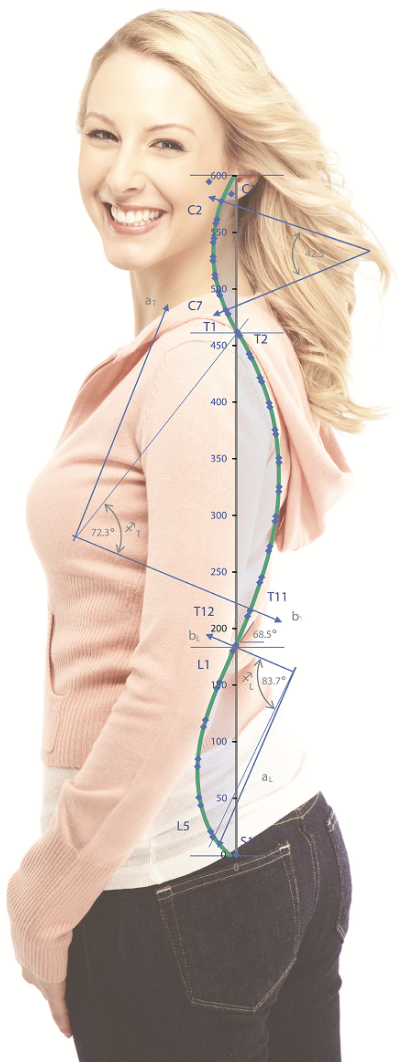




# MODERN CHIROPRACTIC CENTER

## Radiographic Impression Report



Prepared for: Bad Spine  
Patient #: SpineBad2013629000  
Insurance #:  
Gender: Male  
Date of Birth: 8/7/1954  
Address:  
  
Evaluation Date: 6/29/2013  
Date X-Ray Taken: 6/29/2013

Prepared by:  
Nasium Clinic  
Someplace Drive  
Somewhere Cityville, Florida  
34653



**Radiographic Impression Report**

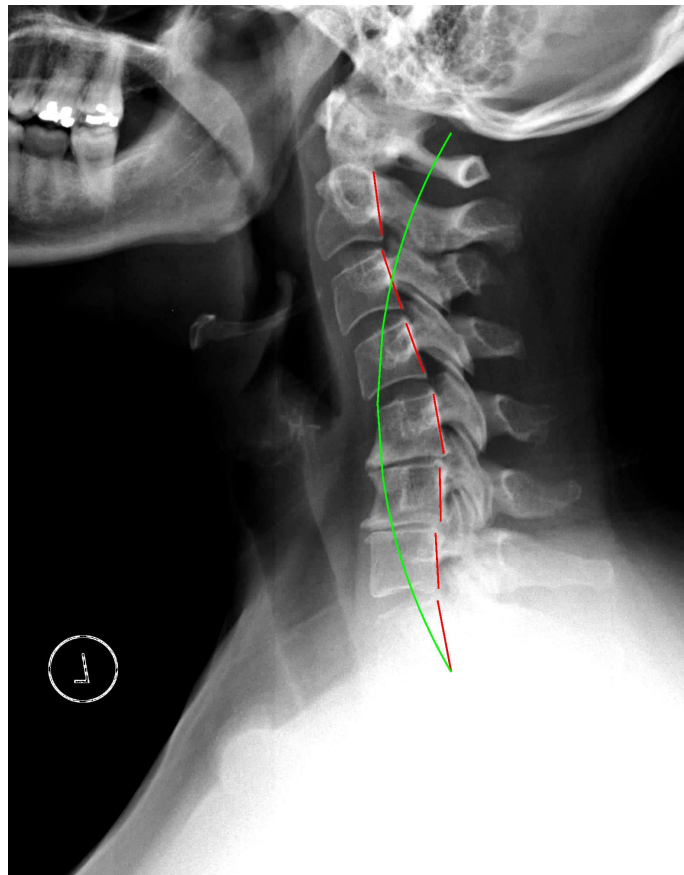
**Lateral Cervical Projection**

**Name: Bad Spine**  
**Date of Birth: 8/7/1954**

**X-Ray was obtained: 6/29/2013**

**Date of Digitization: 6/29/2013**

Mr. Bad Spine's x-rays were analyzed utilizing the PostureRay® computerized X-ray digitizing system with impressions interpreted by Dr. Joe Ferrantelli. X-Ray digitization for spinal biomechanics has been shown to be valid when compared to standard hand drawn methods. The patient's findings were then compared to established normals at each level and then globally. The X-Ray mensuration method used in analyzing this patient have been studied for reliability and validity and these results are as follows:



**Anterior**

**Posterior**

This green curved line represents the Normal Spinal Position and expected path of the posterior longitudinal ligament.

This red line represents the patient's position and the path of the posterior longitudinal ligament.



**Radiographic Impression Report**

**Lateral Cervical Projection**

**Spinal Biomechanics Compared to Normal**

| Segments Analyzed | RRA Normal Values | RRA Patient Values | Difference From Normal | Segmental Translations |
|-------------------|-------------------|--------------------|------------------------|------------------------|
| C1 to Horiz.      | -29.0°            | -27.9°             | 3.8%                   |                        |
| C2-C3             | -10.0°            | -11.3°             | 13.0%                  | -1.7 mm                |
| C3-C4             | -8.0°             | -1.1°              | 86.2%                  | -0.7 mm                |
| C4-C5             | -8.0°             | 9.9°               | 223.8%                 | 0.9 mm                 |
| C5-C6             | -8.0°             | 8.8°               | 210.0%                 | -1.6 mm                |
| C6-C7             | -8.0°             | -2.1°              | 73.8%                  | -1.7 mm                |
| C7-T1             | -8.0°             | -7.6°              | 5.0%                   | -1.2 mm                |

RRA = Relative Rotational Angle of Measurement

| Global Analysis              | Normal Values | Patient Values | Diff. From Normal |
|------------------------------|---------------|----------------|-------------------|
| ARA C2-C7 (Segmental Sum.)   | -42°          | 4.2°           | 110.0%            |
| ARA C2-C7 (Global)           | -42°          | 4.2°           | 110.0%            |
| Translation C2-C7            | 0 mm          | 18.1 mm        | 18.1 mm           |
| C7 Post. Tangent to Vert.    | 21.5°         | 3.2°           | 85.1%             |
| T1 Post. Tangent to Vert.    | 26.5°         | 10.8°          | 59.2%             |
| CBP C1-S1                    | 0 mm          | 55.4 mm        | 55.4 mm           |
| C7 Centroid - S1 Post. Sup.  | 0 mm          | 23.5 mm        | 23.5 mm           |
| T1 Post. Inf.- S1 Post. Inf. | 0 mm          | 19.7 mm        | 19.7 mm           |

ARA = Absolute Rotational Angle of Measurement

Direction of measured displacements are indicated using the right-hand Cartesian coordinate system method in biomechanics. Consequently a "-" negative sign preceding a measured value indicates posterior translation for linear movements; and a "-" preceding angular measurements indicate relative segmental or global extension rotational movement.

| Cervical Morphology                       | Average Values | Patient Values | Diff. From Average |
|---|----------------|----------------|--------------------|
| Posterior tangent sternal incidence angle | 73°            | 59.6°          | 18.4%              |
| Cervical Tilt Angle                       | 46.5°          | 48.8°          | 4.9%               |
| Tip of the Dens offset to Sella Turcica   | n/a            | 8.4 mm         | n/a                |
| Sella Turcica horiz.offset to Manubrium   | n/a            | 48.0 mm        | n/a                |
| C0-C1 Chamberlain's to APL                | n/a            | 10.4°          | n/a                |
| C2 Pos. body of C2 relative to APL        | n/a            | 58.6°          | n/a                |
| T1 Centroid horiz offset to manubrium     | n/a            | 53.1 mm        | n/a                |
| T1 Centroid vertical offset to manubrium  | n/a            | 41.8 mm        | n/a                |
| T1 Endplate line to horizontal            | n/a            | 16.4°          | n/a                |
| Thoracic Inlet Incidence Angle            | n/a            | 62.2°          | n/a                |

APL = Atlas Plane Line

Direction of measured displacements are indicated using the right-hand Cartesian coordinate system method in biomechanics. Consequently a "-" negative sign preceding a measured value indicates posterior translation for linear movements; and a "-" preceding angular measurements indicate relative segmental or global extension rotational movement.



**Radiographic Impression Report**

**Lateral Cervical Projection**

| Upper Cervical Measurements          | Normal Values | Patient Values | Clinical Significance |
|--------------------------------------|---------------|----------------|-----------------------|
| Powers Ratio                         | 0.9 to 1      | 1.0            | WNL                   |
| Basilar Impression (Macrae's method) | n/a           | WNL            | WNL                   |
| Atlanto-Dental Interspace            | ≤ 3 mm        | 1.5 mm         | WNL                   |
| Spinal Canal Diameter                | > 13 mm       | 24.8 mm        | WNL                   |
| Chamberlain's line to horizontal     | n/a           | -13.5°         | n/a                   |

WNL = Within Normal Levels

**Impressions and Assessment**

The posterior tangent method of radiographic analysis has been studied extensively for both validity and reliability<sup>[1;2-5]</sup>, and has been shown to be a superior method of analysis for biomechanical assessment over the Cobb method of x-ray analysis for sagittal cervical spine.<sup>[3]</sup> Using this radiographic analysis technique, the normal cervical lordosis measured from C2-C7 for a normal average population was found to measure -34° with ideal alignment measuring -42°.<sup>[1;2]</sup> (Note that the negative sign preceding the measurement of degree indicates direction, thus the normal Lordotic/extended position and an abnormal flexion angle/kyphosis is noted by a positive angle). There is a statistically significant association between cervical pain and lordosis < -20° and a "clinically normal" range for cervical lordosis of -31° to -40°.<sup>[6]</sup> Further, there is no evidence that hypertonicity as seen in muscle spasms in muscle groups responsible for anterior cervical translation and head flexion have any significant impact on cervical lordosis.<sup>[7]</sup>

As noted in this computerized analysis, Mr. Bad Spine's cervical spine measures 4.2°. According to recent research, Mr. Bad Spine's cervical spine alignment is predictive of chronic neck pain.<sup>[1]</sup> This is a loss from the expected normal lordosis by 110.0%. Regarding anterior cervical translation (weight bearing) findings of less than 15mm has been established as a normal.<sup>[1;2]</sup> Mr. Bad Spine has an abnormal anterior cervical translation from C2 relative to C7 of 18.1mm.

Disc thinning noted C6/7. Disc thinning noted C5/6. moderate to severe spondylosis is noted. No acute bony abnormalities or osseous disease.

**References**

- [1] Harrison DD, Harrison DE, Janik TJ et al. Modeling of the sagittal cervical spine as a method to discriminate hypolordosis: results of elliptical and circular modeling in 72 asymptomatic subjects, 52 acute neck pain subjects, and 70 chronic neck pain subjects. Spine (Phila Pa 1976.) 2004;29:2485-92.
- [2] Harrison DD, Troyanovich SJ, Harrison DE et al. A normal sagittal spinal configuration: a desirable clinical outcome. J.Manipulative Physiol Ther. 1996;19:398-405.
- [3] Harrison DE, Harrison DD, Cailliet R et al. Cobb method or Harrison posterior tangent method: which to choose for lateral cervical radiographic analysis. Spine (Phila Pa 1976.) 2000;25:2072-8.
- [4] Harrison DE, Holland B, Harrison DD et al. Further reliability analysis of the Harrison radiographic line-drawing methods: crossed ICCs for lateral posterior tangents and modified Risser-Ferguson method on AP views. J.Manipulative Physiol Ther. 2002;25:93-8.
- [5] Jackson BL, Harrison DD, Robertson GA et al. Chiropractic biophysics lateral cervical film analysis reliability. J.Manipulative.Physiol.Ther. 1993;16:384-91.
- [6] McAviney J, Schulz D, Bock R et al. Determining the relationship between cervical lordosis and neck complaints. J.Manipulative Physiol Ther. 2005;28:187-93.
- [7] Fedorchuk, CA, McCoy M, Lightstone DF, et al. Impact of Isometric Contraction of Anterior Cervical Muscles on Cervical Lordosis. J Radiol Case Rep. 2016 Sep 30;10(9):13-25. eCollection 2016



**Radiographic Impression Report**

**Lateral Cervical Flexion/Extension**

**Name: Bad Spine**  
**Date of Birth: 8/7/1954**

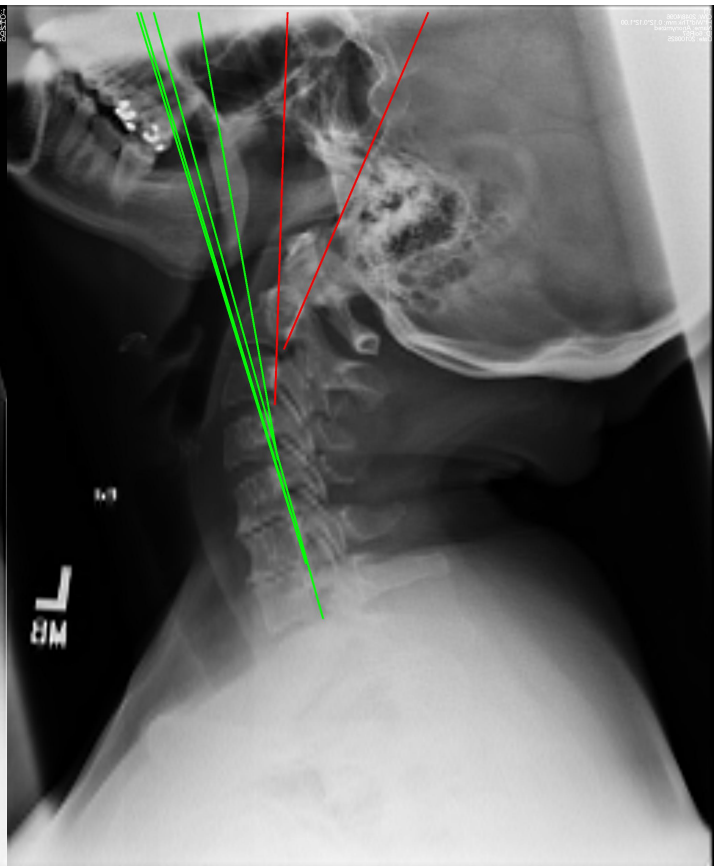
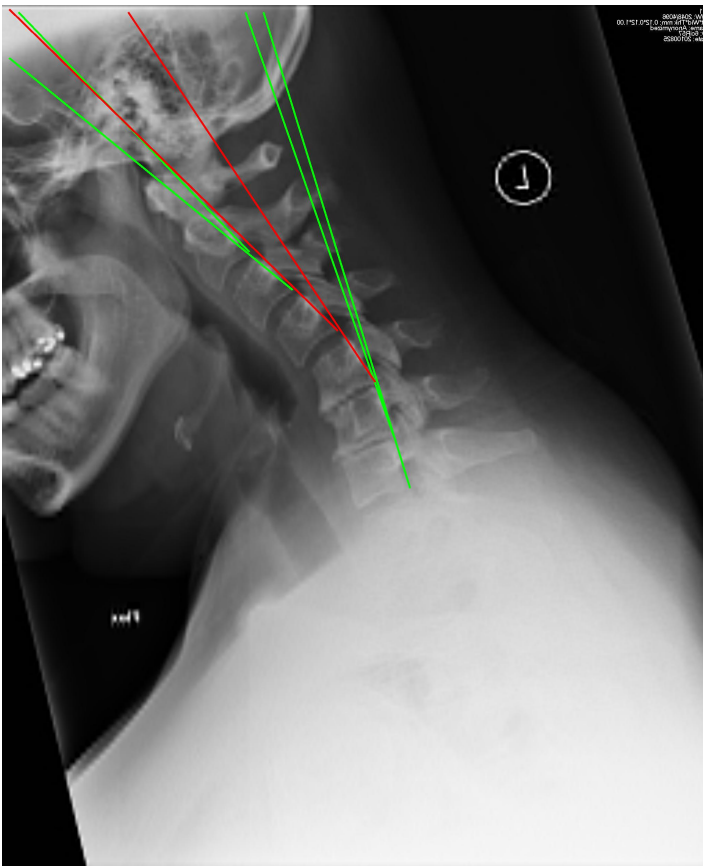**X-Ray was obtained: 6/29/2013**

**Date of Digitization: 6/29/2013**

Mr. Bad Spine's x-rays were analyzed utilizing the PostureRay® computerized X-ray digitizing system with impressions interpreted by Dr. Joe Ferrantelli. X-Ray digitization for spinal biomechanics has been shown to be valid when compared to standard hand drawn methods. The patient's findings were then compared to established normals at each level and then globally. The X-Ray mensuration method used in analyzing this patient have been studied for reliability and validity and these results are as follows:

**Flexion**

**Extension**



**Anterior**

**Posterior**

**Posterior**

**This red line represents the posterior tangent lines of mensuration and exceeds normal allowable segmental motion indicating ligament laxity.**

**This green line represents the posterior tangent lines of mensuration and appears to be stable with no significant ligamentous laxity.**



**Radiographic Impression Report**

**Lateral Cervical Flexion/Extension**

**Flexion/Extension Values**

| Segment      | Flexion RRA*  | Extension RRA* | Angular Excursion** | Flexion Translation*** | Extension Translation*** | Translational Excursion |
|--------------|---------------|----------------|---------------------|------------------------|--------------------------|-------------------------|
| C1 to Horiz. | 12.8°         | -61.0°         |                     |                        |                          |                         |
| C2-C3        | -6.8°         | <b>-21.4°</b>  | 14.6°               | -1.2 mm                | -2.9 mm                  | 1.7 mm                  |
| C3-C4        | 5.1°          | <b>-11.9°</b>  | 17.0°               | 0.2 mm                 | -2.7 mm                  | 2.9 mm                  |
| C4-C5        | <b>11.9°</b>  | -7.0°          | 18.9°               | 0.4 mm                 | -1.6 mm                  | 2.0 mm                  |
| C5-C6        | <b>14.4°</b>  | 0.3°           | 14.1°               | 0.3 mm                 | -0.1 mm                  | 0.4 mm                  |
| C6-C7        | 2.1°          | 1.1°           | 1.0°                | 0.0 mm                 | 0.4 mm                   | 0.4 mm                  |
| C7-T1        | Not Digitized | Not Digitized  | n/a                 | Not Digitized          | Not Digitized            | n/a                     |

RRA = Relative Rotational Angle of Measurement  
 \* Values in Red Exceed Established Normal of 11°  
 \*\* Values in Red Exceed Established Normal of 23°  
 \*\*\* Values in Red Exceed Established Normal of 3.5mm

| Global Analysis                 | Flexion       | Extension     | Global Excursion |
|---------------------------------|---------------|---------------|------------------|
| ARA C2-C7 (Segmental Summation) | 26.7°         | -38.9°        | 65.6°            |
| ARA C2-C7 (Global)              | 26.8°         | -38.8°        | 65.6°            |
| Translation C2-C7               | 68.7 mm       | 6.7 mm        | 62.0 mm          |
| C7 Post. Tangent to Vert.       | 17.1°         | 15.6°         | 1.5°             |
| T1 Post. Tangent to Vert.       | Not Digitized | Not Digitized | n/a              |

ARA = Absolute Rotational Angle of Measurement  
 Direction of measured displacements are indicated using the right-hand Cartesian coordinate system method in biomechanics. Consequently a "-" negative sign preceding a measured value indicates posterior translation for linear movements; and a "-" preceding angular measurements indicate relative segmental or global extension rotational movement.

| Cervical Morphology                | Flexion | Extension | Global Excursion |
|------------------------------------|---------|-----------|------------------|
| C0-C1 Chamberlain's to APL         | -16.3°  | 5.7°      | -22.0°           |
| C2 Pos. body of C2 relative to APL | 65.3°   | 56.3°     | 9.1°             |

APL = Atlas Plane Line  
 Direction of measured displacements are indicated using the right-hand Cartesian coordinate system method in biomechanics. Consequently a "-" negative sign preceding a measured value indicates posterior translation for linear movements; and a "-" preceding angular measurements indicate relative segmental or global extension rotational movement.



**Radiographic Impression Report**

**Lateral Cervical Flexion/Extension**

| Upper Cervical Measurements - Flexion | Normal Values | Patient Values | Clinical Significance |
|---------------------------------------|---------------|----------------|-----------------------|
| Powers Ratio                          | 0.9 to 1      | 0.9            | WNL                   |
| Basilar Impression (Macrae's method)  | n/a           | WNL            | WNL                   |
| Atlanto-Dental Interspace             | ≤ 3 mm        | 1.5 mm         | WNL                   |
| Spinal Canal Diameter                 | > 13 mm       | 24.9 mm        | WNL                   |
| Chamberlain's line to horizontal      | n/a           | 35.4°          | n/a                   |

WNL = Within Normal Levels

| Upper Cervical Measurements - Extension | Normal Values | Patient Values | Clinical Significance                           |
|---|---------------|----------------|---|
| Powers Ratio                            | 0.9 to 1      | 1.1            | Anterior Atlantooccipital dislocation may exist |
| Basilar Impression (Macrae's method)    | n/a           | WNL            | WNL   |
| Atlanto-Dental Interspace               | ≤ 3 mm        | 0.7 mm         | WNL   |
| Spinal Canal Diameter                   | > 13 mm       | 27.3 mm        | WNL   |
| Chamberlain's line to horizontal        | n/a           | -51.2°         | n/a   |

WNL = Within Normal Levels

| Upper Cervical Measurements - Flexion + Extension | Normal Values | Patient Values | Clinical Significance |
|---|---------------|----------------|-----------------------|
| C0-C1 Instability                                 | < 25°         | 8.4°           | WNL                   |
| C1-C2 Instability                                 | < 20°         | 12.3°          | WNL                   |

WNL = Within Normal Levels



## Impressions and Assessment

The posterior tangent method of radiographic analysis has been studied extensively for both validity and reliability<sup>[4-8]</sup>, and has been shown to be a superior method of analysis for biomechanical assessment over the Cobb method of x-ray analysis for sagittal cervical spine.<sup>[6]</sup> Normal values for intersegmental motion should not exceed more than 10-11° of angular motion.<sup>[9]</sup> Using the posterior tangent method of radiographic analysis, motion that exceeds 10° has been shown to predict and discriminate minor ligamentous injuries from those patients with true whiplash type ligamentous injuries.<sup>[3]</sup> Corroborating these findings using another method of analysis (inferior endplate assessment), an alteration of motion segment integrity (AOMSI) has been defined as motion at the level in question that is more than 11° greater than at either adjacent level.<sup>[1]</sup> Regarding segmental translational movements, authors have noted that subluxation should be noted with a range of 1.0-3.0mm<sup>[2]</sup> of intersegmental movement with absolute clinical cutoff threshold value of 3.5mm.<sup>[1,9]</sup> Of additional importance, improvement in neutral lateral cervical lordosis has been shown to be associated with significant improvement in the translational and rotational motions of the lower cervical spine. Flexion/extension kinematics are partially dependent on the posture and sagittal curve orientation.<sup>[10]</sup>

There is possible significant damage to the posterior longitudinal ligament and/or posterior intervertebral disc and/or interspinous ligament which is indicated by an increased widening of the posterior intervertebral disc space angulation and increased separation of spinous processes at the following levels: C4-C5, C5-C6.

There is anterior widening of the intervertebral disc space at C2-C3, C3-C4 levels evidenced by excessive segmental extension, which indicates possible damage to the anterior longitudinal ligament and/or intervertebral disc at said level.

- Segmental flexion instability is noted at the following segments: C4-C5 of 11.9°, C5-C6 of 14.4°.
- Segmental extension instability is noted at the following segments: C2-C3 of -21.4°, C3-C4 of -11.9°.
- Segmental angular excursion instability is noted at the following segments: none
- Segmental subluxation for flexion is noted at the following segments: C2-C3 with -1.2 mm.
- Segmental subluxation for extension is noted at the following segments: C2-C3 with -2.9 mm, C3-C4 with -2.7 mm, C4-C5 with -1.6 mm.
- Segmental translational instability for flexion is noted at the following segments: none
- Segmental translational instability for extension is noted at the following segments: none

**Flexion View Impressions:** Very limited global ROM is noted with associated spinal coupling. No acute bony abnormalities or osseous disease.

**Extension View Impressions:** Very limited global ROM is noted with associated spinal coupling most noted mid to lower cervical spine. I suspect delayed instability will appear once more normal global ROM is achieved.





**References**

- [1] Guides to the Evaluation of Permanent Impairment, Fifth Edition. American Medical Association, 2000.
- [2] Green JD, Harle TS, Harris JH, Jr. Anterior subluxation of the cervical spine: hyperflexion sprain. AJNR Am.J.Neuroradiol. 1981;2:243-50.
- [3] Griffiths HJ, Olson PN, Everson LI et al. Hyperextension strain or "whiplash" injuries to the cervical spine. Skeletal Radiol. 1995;24:263-6.
- [4] Harrison DD, Harrison DE, Janik TJ et al. Modeling of the sagittal cervical spine as a method to discriminate hypolordosis: results of elliptical and circular modeling in 72 asymptomatic subjects, 52 acute neck pain subjects, and 70 chronic neck pain subjects. Spine (Phila Pa 1976.) 2004;29:2485-92.
- [5] Harrison DD, Troyanovich SJ, Harrison DE et al. A normal sagittal spinal configuration: a desirable clinical outcome. J.Manipulative Physiol Ther. 1996;19:398-405.
- [6] Harrison DE, Harrison DD, Cailliet R et al. Cobb method or Harrison posterior tangent method: which to choose for lateral cervical radiographic analysis. Spine (Phila Pa 1976.) 2000;25:2072-8.
- [7] Harrison DE, Holland B, Harrison DD et al. Further reliability analysis of the Harrison radiographic line-drawing methods: crossed ICCs for lateral posterior tangents and modified Risser-Ferguson method on AP views. J.Manipulative Physiol Ther. 2002;25:93-8.
- [8] Jackson BL, Harrison DD, Robertson GA et al. Chiropractic biophysics lateral cervical film analysis reliability. J.Manipulative.Physiol.Ther. 1993;16:384-91.
- [9] White AA, III, Johnson RM, Panjabi MM et al. Biomechanical analysis of clinical stability in the cervical spine. Clin.Orthop. 1975;85-96.
- [10] Moustafa IM, et al. Does rehabilitation of cervical lordosis influence sagittal cervical spine flexion extension kinematics in cervical spondylotic radiculopathy subjects? J Back Musculoskelet Rehabil. 2016 Mar 27. doi: 10.3233/BMR-150464.



**Radiographic Impression Report**

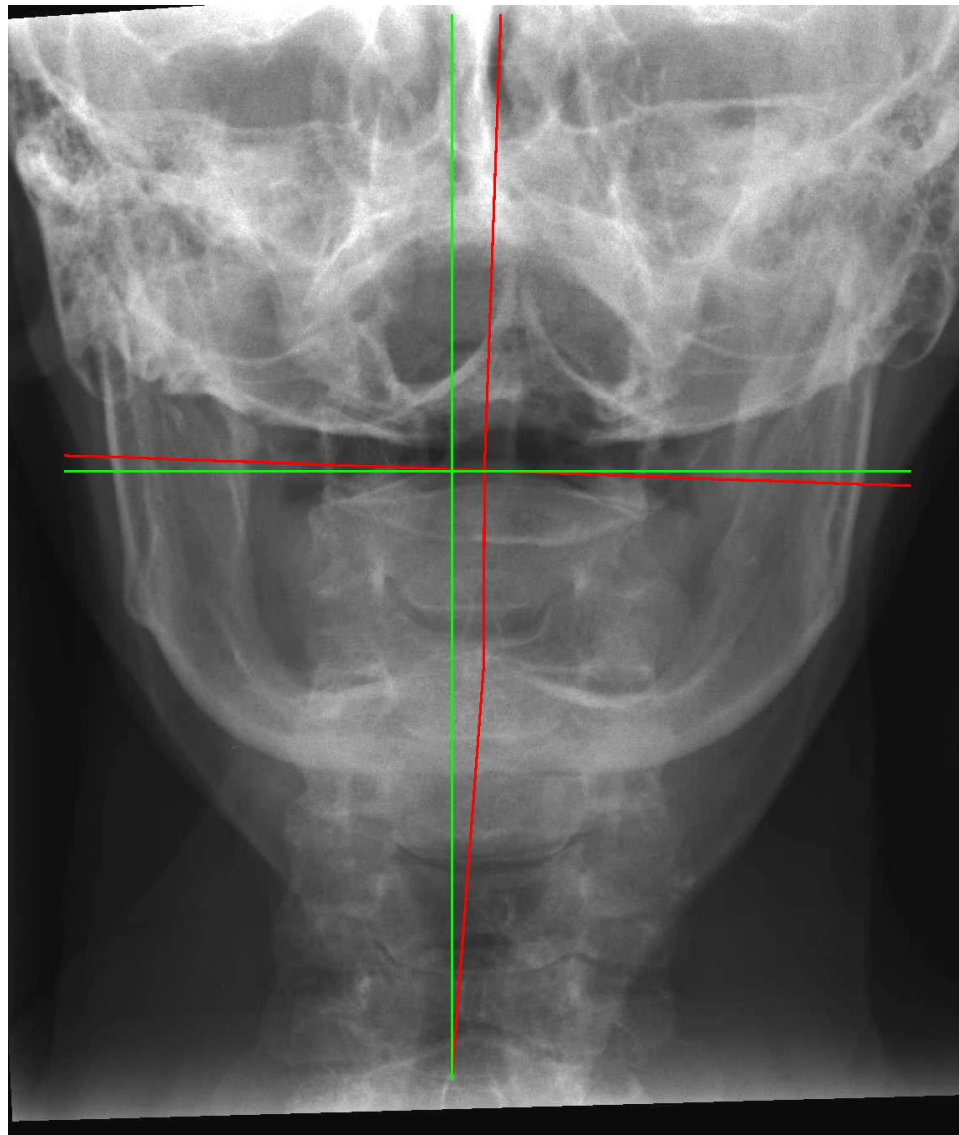
**AP Open Mouth**

**Name: Bad Spine  
Date of Birth: 8/7/1954**

**X-Ray was obtained: 6/29/2013**

**Date of Digitization: 6/29/2013**

Mr. Bad Spine's x-rays were analyzed utilizing the PostureRay® computerized X-ray digitizing system with impressions interpreted by Dr. Joe Ferrantelli. X-Ray digitization for spinal biomechanics has been shown to be valid when compared to standard hand drawn methods. The patient's findings were then compared to established normals at each level and then globally. The X-Ray mensuration method used in analyzing this patient have been studied for reliability and validity and these results are as follows:



**Right**

**Left**

The horizontal green line represents the normal atlas position. The vertical green line is a plumb line, also indicating normal vertical spinal alignment.

The horizontal red line represents the patient's Atlas vertebrae position. Ideally this should superimpose the green normal horizontal line. The red vertically oriented line should superimpose the true green vertical plumb line in spines with normal alignment.



**Radiographic Impression Report**

**AP Open Mouth**

**Neutral Values**

| Global Analysis               | Normal Values | Patient Values | Difference From Normal | Clinical Significance |
|-------------------------------|---------------|----------------|------------------------|-----------------------|
| C0-C1 Lat. Flex. Angle        | 0.0°          | 0.8°           | 0.8°                   | WNL                   |
| C1-C2 Lat. Flex. Angle        | 0.0°          | 1.4°           | 1.4°                   | WNL                   |
| C2-C3 Lat. Flex. Angle        | 0.0°          | 0.9°           | 0.9°                   | WNL                   |
| Left C1-C2 "overhang" margin  | 0.0 mm        | 1.1 mm left    | 1.1 mm                 | WNL                   |
| Right C1-C2 "overhang" margin | 0.0 mm        | 1.5 mm left    | 1.5 mm                 | WNL                   |
| C2 Axial Spinous Rotation     | 0.0°          | 1.8° left      | 1.8°                   |                       |

WNL = Within Normal Levels

Direction of measured displacements are indicated using the right-hand Cartesian coordinate system method in biomechanics. Consequently a "-" negative sign preceding a measured value indicates left translation for linear movements; and a "-" preceding angular measurements indicate relative segmental or global rotational movement to the left.

**Impressions and Assessment**

As noted above in the table for the neutral position, Mr. Bad Spine has a 1.1 mm left shift of C1 relative to the lateral body margin of C2 on the left side. On the patient's right side, there is a 1.5 mm left shift of C1 relative to the lateral body margin of C2.

No acute bony abnormalities or osseous disease. Paraodontoid space is not symmetrical and appears deviated from plumb.



**Radiographic Impression Report**

**AP Cervical Projection**

**Name: Bad Spine**  
**Date of Birth: 8/7/1954**

**X-Ray was obtained: 6/29/2013**

**Date of Digitization: 6/29/2013**

Mr. Bad Spine's x-rays were analyzed utilizing the PostureRay® computerized X-ray digitizing system with impressions interpreted by Dr. Joe Ferrantelli. X-Ray digitization for spinal biomechanics has been shown to be valid when compared to standard hand drawn methods. The patient's findings were then compared to established normals at each level and then globally. The X-Ray mensuration method used in analyzing this patient have been studied for reliability and validity and these results are as follows:

**Spinal Biomechanics Compared to Normal**

| Global Analysis   | Normal Values | Patient Values | Difference From Normal |
|-------------------|---------------|----------------|------------------------|
| RZA T5            | 0°            | -3.3°          | 3.3°                   |
| CDA C2-T5         | 0°            | 0.8°           | 0.8°                   |
| Translation C2-T5 | 0 mm          | 9.8 mm         | 9.8 mm                 |

CDA = Cervico-dorsal Angle and is a measure of the mid cervical angle  
RZA = Rotation Angle relative to true vertical of the lower cervical and upper thoracic spine

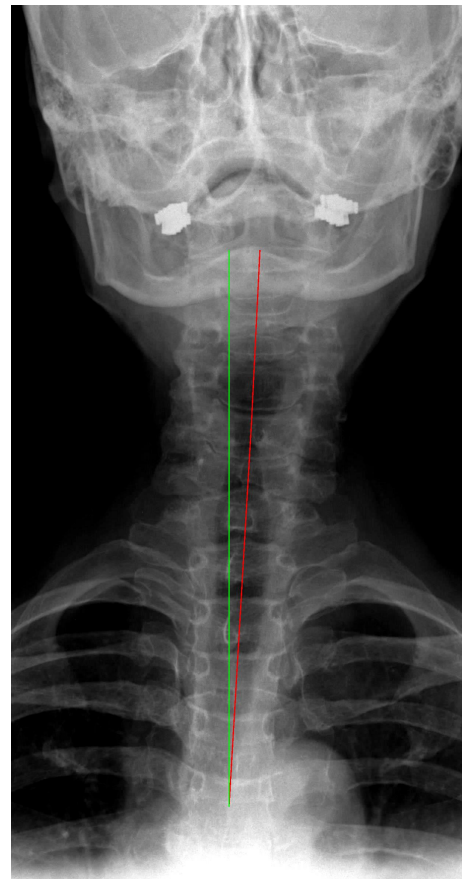
**Impressions and Assessment**

The x-ray analysis performed on this AP cervico-thoracic view has been studied for reliability and demonstrated both intraexaminaer and interexaminer reliability.[1] As noted above in the table, Mr. Bad Spine's cervical spine is translated (listed) from plumb by 9.8 mm to the left. Of importance is that the patient has a mid neck abnormal angle of 0.8 degrees to the right. The patient has an angular displacement from normal (plumb) of the lower cervical and upper thoracic spine of 3.3 degrees to the left.

No acute bony abnormalities or osseus disease. Mild to moderate diffuse degenerative changes noted.

**References**

[1] Troyanovich SJ, Harrison DE, et al. Chiropractic Biophysics Digitized Radiographic Mensuration Analysis of the Anteroposterior Cervicothoracic View: A Reliability Study. JMPT 2000 Sep Vol. 23, Num 7: 476-482.



**Right** **Left**

This green line represents normal spinal position.

This red line represents the patient's alignment and the projected centers of mass of the spine.



**Radiographic Impression Report**

**Nasium Cervical/Thoracic  
Projection**

**Name: Bad Spine**  
**Date of Birth: 8/7/1954**

**X-Ray was obtained: 6/29/2013**

**Date of Digitization: 6/29/2013**

Mr. Bad Spine's x-rays were analyzed utilizing the PostureRay® computerized X-ray digitizing system with impressions interpreted by Dr. Joe Ferrantelli. X-Ray digitization for spinal biomechanics has been shown to be valid when compared to standard hand drawn methods. The patient's findings were then compared to established normals at each level and then globally. The X-Ray mensuration method used in analyzing this patient have been studied for reliability and validity and these results are as follows:

**Spinal Biomechanics Compared to Normal**

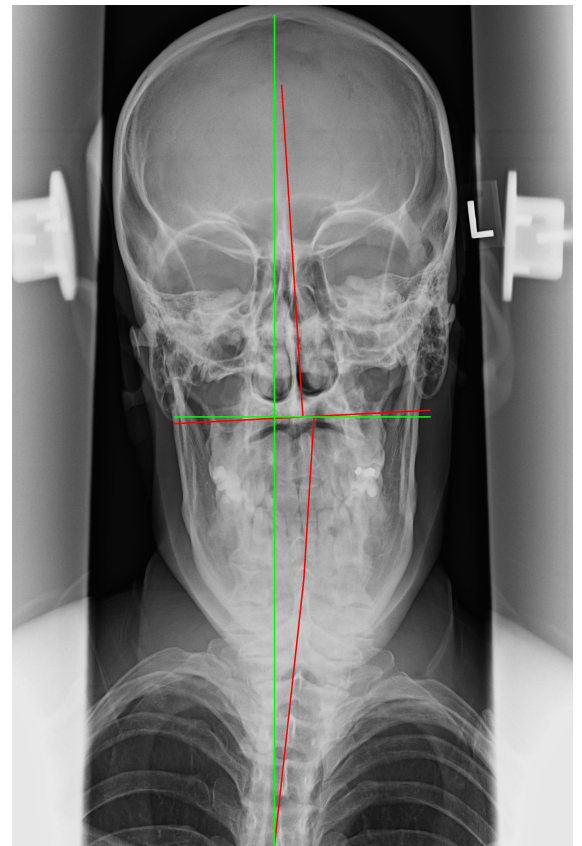
| Global Analysis        | Normal Values | Patient Values     | Diff. From Normal |
|------------------------|---------------|--------------------|-------------------|
| CDA C2-T7 (C5 apex)    | 0°            | 5.8°               | 5.8°              |
| Left C1-C2 "overhang"  | 0 mm          | 1.2 mm             | 1.2 mm            |
| Right C1-C2 "overhang" | 0 mm          | 1.7 mm             | 1.7 mm            |
| C2 Spinous Rotation    | 0°            | 0.3°               | 0.3°              |
| Upper Angle            | 0°            | 0.7° right (89.3°) | 0.7°              |
| Lower Angle            | 0°            | 6.6° right (83.4°) | 6.6°              |
| Translation C2-T7      | 0 mm          | 14.6 mm            | 14.6 mm           |

CDA = Cervico-dorsal Angle and is a measure of the mid cervical angle

**Impressions and Assessment**

As noted in the table, Mr. Bad Spine has a 1.2 mm left shift of C1 relative to the lateral body margin of C2 on the left side. On the patient's right side, there is a 1.7 mm left shift of C1 relative to the lateral body margin of C2. Concerning the angular findings of atlas relative to the skull, Mr. Bad Spine's spine denotes an upper angle measurement of 0.7 degrees to the right and a lower angle of 6.6 degrees to the right. Ideal alignment in this region of the upper cervical region is should approximate 0 degrees of offset of the upper angle and lower angle - meaning the skull sits perpendicular to the Atlas bone. The spine is translated (listed) from plumb by 14.6 mm to the left. Of importance, is that the patient has a mid neck cervico-dorsal angle of 5.8 degrees to the right.

No acute bony abnormalities or osseus disease. Dens and C1 appear unremarkable for bony abnormalities.



**Right**

**Left**

The green line represents normal spinal position.

The red line represents the patient's alignment and the projected centers of mass of the spine.



**Radiographic Impression Report**

**Lateral Thoracic Projection**

**Name: Bad Spine**  
**Date of Birth: 8/7/1954**

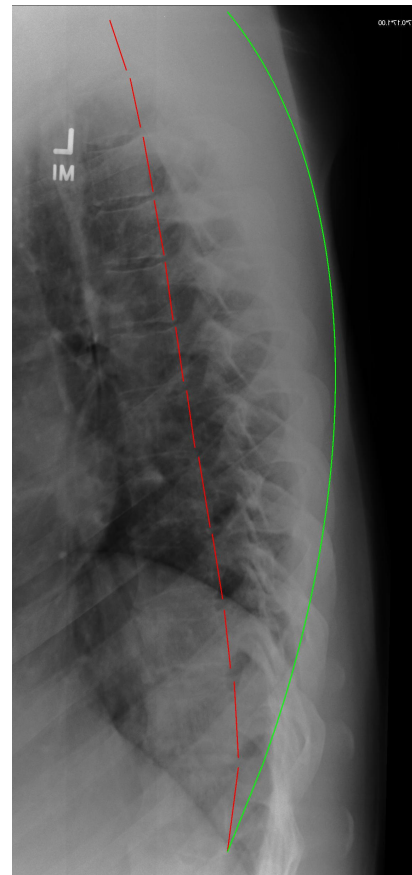
**X-Ray was obtained: 6/29/2013**

**Date of Digitization: 6/29/2013**

Mr. Bad Spine's x-rays were analyzed utilizing the PostureRay® computerized X-ray digitizing system with impressions interpreted by Dr. Joe Ferrantelli. X-Ray digitization for spinal biomechanics has been shown to be valid when compared to standard hand drawn methods. The patient's findings were then compared to established normals at each level and then globally. The X-Ray mensuration method used in analyzing this patient have been studied for reliability and validity and these results are as follows:

**Spinal Biomechanics Compared to Normal**

| Segments Analyzed  | RRA Normal Values | RRA Patient Values | Difference From Normal | Segmental Translations |
|--------------------|-------------------|--------------------|------------------------|------------------------|
| T1-T2              | -1.0°             | 6.4°               | 740.0%                 | 2.3%                   |
| T2-T3              | 4.0°              | 1.8°               | 55.0%                  | 0.5%                   |
| T3-T4              | 5.0°              | 0.0°               | 100.0%                 | -1.2%                  |
| T4-T5              | 6.0°              | 2.6°               | 56.7%                  | -0.1%                  |
| T5-T6              | 5.0°              | -0.5°              | 110.0%                 | 2.7%                   |
| T6-T7              | 6.0°              | -0.1°              | 101.7%                 | 2.5%                   |
| T7-T8              | 6.0°              | -1.0°              | 116.7%                 | 3.1%                   |
| T8-T9              | 4.0°              | 0.2°               | 95.0%                  | 1.5%                   |
| T9-T10             | 3.0°              | 3.0°               | 0.0%                   | 0.5%                   |
| T10-T11            | 3.0°              | 3.0°               | 0.0%                   | 3.0%                   |
| T11-T12            | 3.0°              | 10.5°              | 250.0%                 | 0.5%                   |
| Global Analysis    |                   | Normal Values      | Patient Values         | Difference From Normal |
| ARA T1-T12         |                   | 44.0°              | 25.8°                  | 41.4%                  |
| ARA T2-T11         |                   | 42.0°              | 8.9°                   | 78.8%                  |
| ARA T3-T10         |                   | 37.0°              | 4.1°                   | 88.9%                  |
| Translation T1-T12 |                   | 0.0 mm             | 49.0 mm                | 49.0 mm                |



**Anterior** **Posterior**

This green curve represents the Normal Spinal Position and expected path of the posterior longitudinal ligament.

This red line represents the patient's position and the path of the posterior longitudinal ligament.

RRA = Relative Rotational Angle of Measurement  
ARA = Absolute Rotational Angle of Measurement  
Direction of measured displacements are indicated using the right-hand Cartesian coordinate system method in biomechanics. Consequently a "-" negative sign preceding a measured value indicates posterior translation for linear movements; and a "-" preceding angular measurements indicate relative segmental or global extension rotational movement.

Values derived from sectional view for higher level of validity

**Impressions and Assessment**

The x-ray mensuration analysis used in this analysis has been studied and shown to be superior and more valid to methods such as Centroid and Cobb analysis of the thoracic kyphosis.<sup>[1]</sup> The normal thoracic kyphosis has an established elliptical shape with an overall normal angulation measuring 44° T1-T12, 42° T2-T11, and 37° T3-T10.<sup>[2]</sup> As noted above in the table, Mr. Bad Spine's thoracic kyphosis is decreased 41.4% compared to normal. The patient has a forward thoracic translation from T1 relative to T12 of 49.0 mm. There is an overall hypokyphosis noted in the thoracic spine.

No acute bony abnormalities or osseous disease. Mild diffuse degenerative changes are noted.



**References**

- [1] Harrison DE, Cailliet R, Harrison DD et al. Reliability of Centroid, Cobb, and Harrison Posterior Tangent Methods: Which to Choose for Analysis of Thoracic Kyphosis JMPT 2000 Sep Vol. 23, Num 7: 476-482.
- [2] Harrison DE, Janik T, Harrison DD, et al. Can the Thoracic Kyphosis be Modeled with a Simple Geometric Shape? The Results of Circular and Elliptical Modeling in 80 Asymptomatic Patients. J Spinal Disord Tech. 2002 Jun;15(3):213-20.

A blue ink handwritten signature, likely of Dr. Joe Ferrantelli, located at the bottom center of the page.



**Radiographic Impression Report**

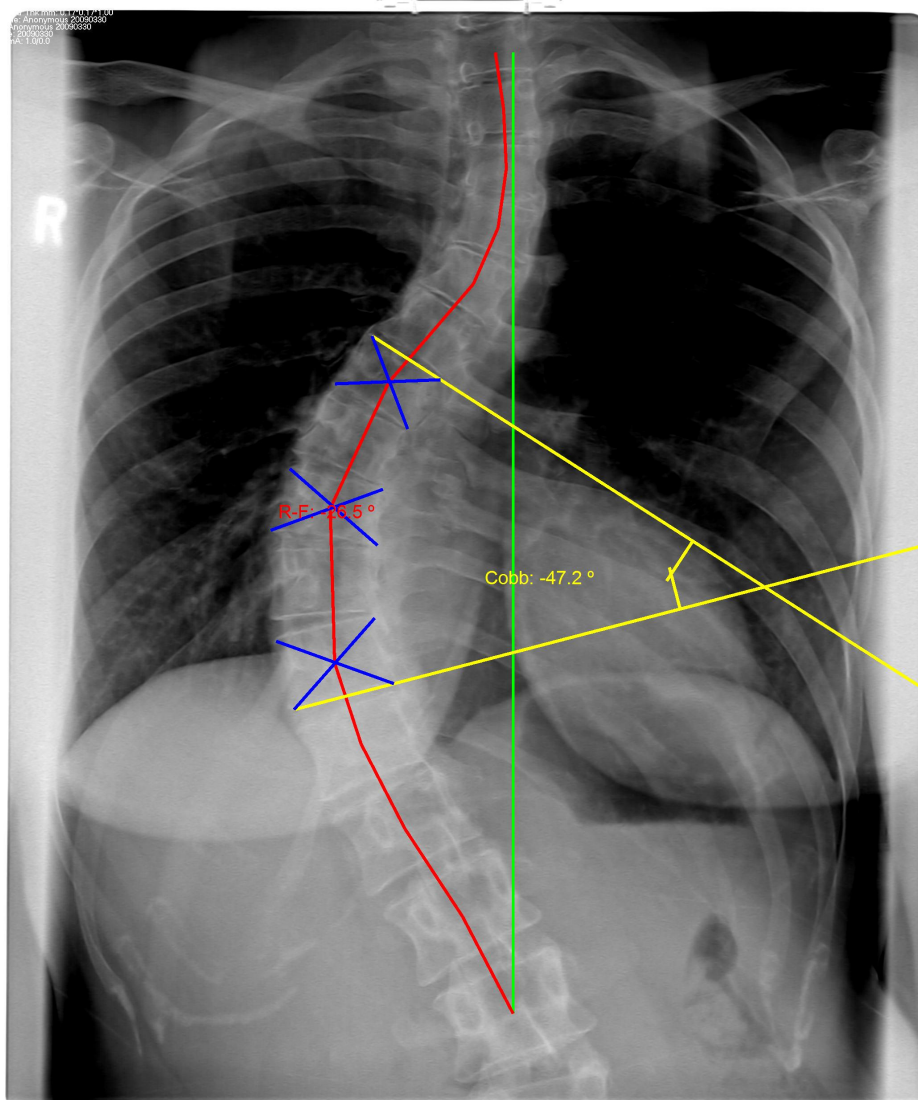
**AP Thoracic Scoliosis Projection**

**Name: Bad Spine**  
**Date of Birth: 8/7/1954**

**X-Ray was obtained: 6/29/2013**

**Date of Digitization: 6/29/2013**

Mr. Bad Spine's x-rays were analyzed utilizing the PostureRay® computerized X-ray digitizing system with impressions interpreted by Dr. Joe Ferrantelli. X-Ray digitization for spinal biomechanics has been shown to be valid when compared to standard hand drawn methods. The patient's findings were then compared to established normals at each level and then globally. The X-Ray mensuration method used in analyzing this patient have been studied for reliability and validity and these results are as follows:



**Right**

**Left**

This green line represents normal spinal position.

This red line represents the patient's alignment and the projected centers of mass of the spine.  
R-F: Risser-Ferguson Method of analysis  
Cobb: Cobb Method of analysis





**Spinal Biomechanics Compared to Normal**

| Global Analysis                   | Normal Values | Patient Values | Difference From Normal |
|-----------------------------------|---------------|----------------|------------------------|
| Risser-Ferguson Angle T7-T11 (T9) | 0.0°          | -26.5°         | 26.5°                  |
| Cobb Angle T7-T11                 | 0.0°          | -47.2°         | 47.2°                  |
| Translation at Apex T7-T11 (T9)   | 0.0 mm        | -1.7 mm        | 1.7 mm                 |
| Translation T7-T11                | 0.0 mm        | 20.9 mm        | 20.9 mm                |
| Translation T1-L3                 | 0.0 mm        | -7.3 mm        | 7.3 mm                 |
| Clavicular angle to horizontal    | 0.0°          | Not Digitized  | Not Digitized          |

Direction of measured displacements are indicated using the right-hand Cartesian coordinate system method in biomechanics. Consequently a "-" negative sign preceding a measured value indicates left translation for linear movements; and a "-" preceding angular measurements indicate relative segmental or global rotational movement to the left.

Mr. Bad Spine has a 1 curve scoliosis at T7-T11 with the apex on the right at T9. Using the Risser-Ferguson method of analysis, Mr. Bad Spine's scoliosis measures -26.5 degrees (severe), and using the Cobb method of analysis measures -47.2 degrees (severe).

No acute bony abnormalities or osseous disease. Mild diffuse degenerative changes are noted. Scoliosis as noted.



**Radiographic Impression Report**

**Lateral Lumbar Projection**

**Name: Bad Spine**

**X-Ray was obtained: 6/29/2013**

**Date of Digitization: 6/29/2013**

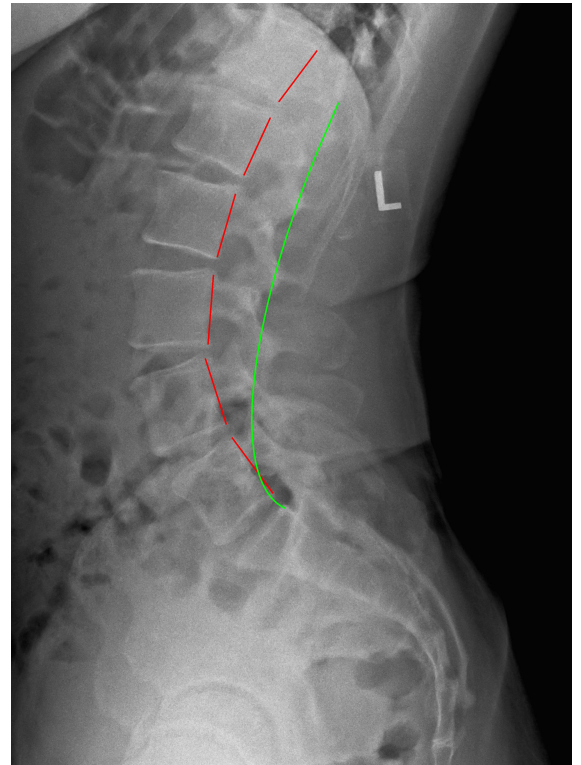
**Date of Birth: 8/7/1954**

Mr. Bad Spine's x-rays were analyzed utilizing the PostureRay® computerized X-ray digitizing system with impressions interpreted by Dr. Joe Ferrantelli. X-Ray digitization for spinal biomechanics has been shown to be valid when compared to standard hand drawn methods. The patient's findings were then compared to established normals at each level and then globally. The X-Ray mensuration method used in analyzing this patient have been studied for reliability and validity and these results are as follows:

**Spinal Biomechanics Compared to Normal**

| Segments Analyzed | RRA Normal Values | RRA Patient Values | Difference From Normal | Segmental Translations |
|-------------------|-------------------|--------------------|------------------------|------------------------|
| T112-L1           | -1°               | -12.2°             | 1120.0%                | -0.2 mm                |
| L1-L2             | -5°               | -8.6°              | 72.0%                  | -1.2 mm                |
| L2-L3             | -6°               | -11.7°             | 95.0%                  | -1.6 mm                |
| L3-L4             | -9°               | -22.2°             | 146.7%                 | -3.5 mm                |
| L4-L5             | -19°              | -18.7°             | 1.6%                   | -1.6 mm                |
| L5-S1             | -33°              | -17.4°             | 47.3%                  | -1.3 mm                |
| Sacral Base       | 40°               | 47.8°              | 19.5%                  |                        |

| Global Analysis              | Normal Values | Patient Values | Diff. From Normal |
|------------------------------|---------------|----------------|-------------------|
| ARA L1-L5                    | -40°          | -61.1°         | 52.7%             |
| Translation T12-S1           | 0 mm          | 25.9 mm        | 25.9 mm           |
| Pelvic Tilt                  | 50°           | Not Digitized  | Not Digitized     |
| Pelvic Incidence             | 56°           | Not Digitized  | Not Digitized     |
| CBP PTPIA                    | 67°           | Not Digitized  | Not Digitized     |
| CBP C1-S1                    | 0 mm          | 55.4 mm        | 55.4 mm           |
| C7 Centroid - S1 Post. Sup.  | 0 mm          | 23.5 mm        | 23.5 mm           |
| T1 Post. Inf.- S1 Post. Inf. | 0 mm          | 19.7 mm        | 19.7 mm           |



**Anterior** **Posterior**

This green line represents the Normal Spinal Position and expected path of the posterior longitudinal ligament.

This red line represents the patient's position and the path of the posterior longitudinal ligament.

RRA = Relative Rotational Angle of Measurement  
 ARA = Absolute Rotational Angle of Measurement  
 PTPIA = Posterior Tangent Pelvic Incidence Angle  
 WNL = Within Normal Levels  
 Values derived from sectional view for higher level of validity



### Impressions and Assessment

The x-ray mensuration utilized in this assessment has been studied and noted to have high inter- and intra-examiner reliability<sup>[1]</sup> and also to be preferred method of analysis when compared to Cobb and Centroid, and Trall analysis especially when the angle of lordosis is to be measured.<sup>[2]</sup> Normal lordosis for the lumbar spine has been demonstrated and for individuals with normal morphology, it has been found that those with a hyperlordosis were associated with acute lumbar pain, compared to those with chronic lumbar pain demonstrating a hypolordosis. Thus altered configurations of the normal elliptical anthropometric model of the lumbar lordosis may clinically correlate with the development of degenerative changes in the spinal tissues and production of low back pain syndromes.<sup>[3]</sup>

As noted above in the table, Mr. Bad Spine has an overall increase from normal lordosis by 52.8%. The patient has a anterior translation from T12 relative to S1 of 25.9 mm.

No acute bony abnormalities or osseus disease.

### References

- [1] Troyanovich SJ, Robertson GA, Harrison DD, Holland B. Intra- and interexaminer reliability of the chiropractic biophysics lateral lumbar radiographic mensuration procedure. *J Manipulative Physiol Ther.* 1995 Oct;18(8):519-24.
- [2] Harrison DE, Harrison DD, et al. Radiographic Analysis of Lumbar Lordosis, Centroid, Cobb, TRALL, and Harrison Posterior Tangent Methods. *Spine (Phila Pa 1976).* 2001 Jun 1;26(11):E235-42.
- [3] (3) Harrison DD, Cailliet R et al. Elliptical modeling of the sagittal lumbar lordosis and segmental rotation angles as a method to discriminate between normal and low back pain subjects. *J Spinal Disord.* 1998 Oct;11(5):430-9.



**Radiographic Impression Report**

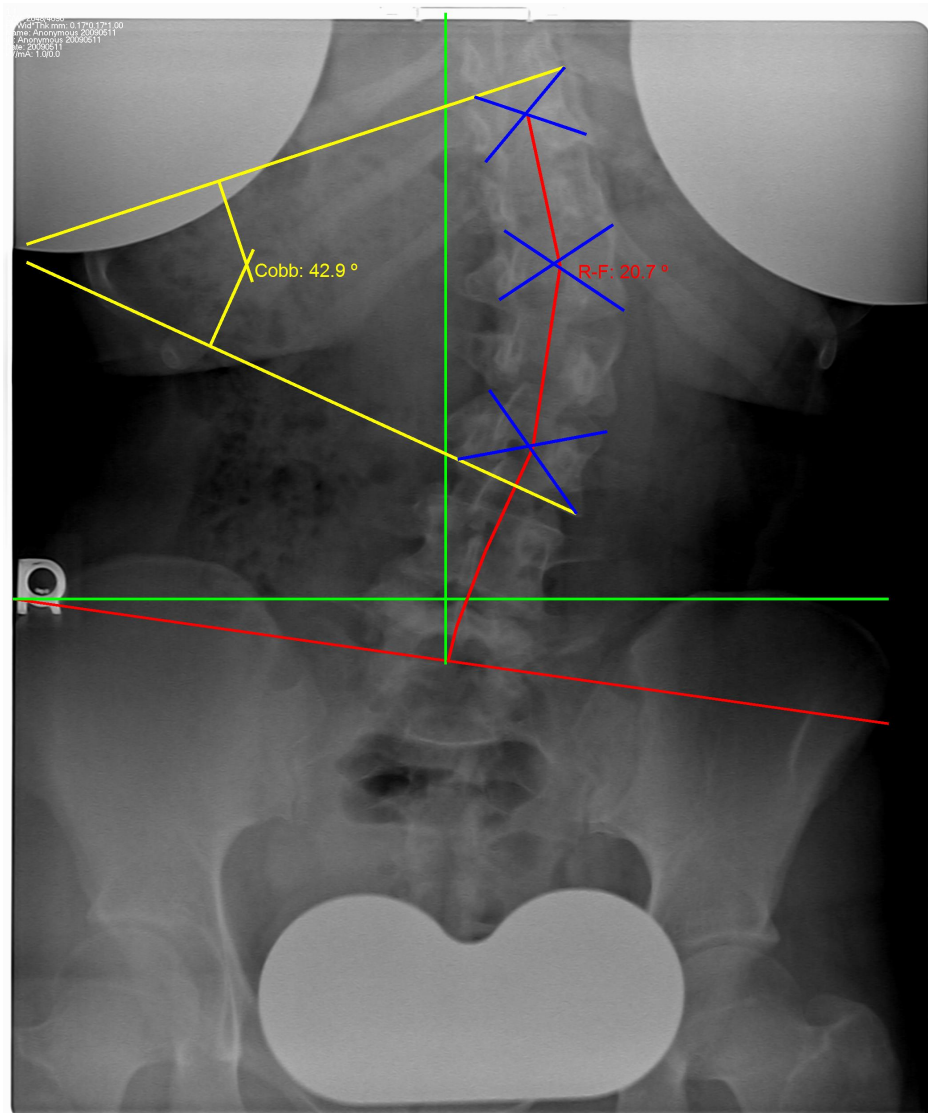
**AP Lumbar Scoliosis Projection**

**Name: Bad Spine**  
**Date of Birth: 8/7/1954**

**X-Ray was obtained: 6/29/2013**

**Date of Digitization: 6/29/2013**

Mr. Bad Spine's x-rays were analyzed utilizing the PostureRay® computerized X-ray digitizing system with impressions interpreted by Dr. Joe Ferrantelli. X-Ray digitization for spinal biomechanics has been shown to be valid when compared to standard hand drawn methods. The patient's findings were then compared to established normals at each level and then globally. The X-Ray mensuration method used in analyzing this patient have been studied for reliability and validity and these results are as follows:



**Right**

**Left**

This green line represents normal spinal position.

This red line represents the patient's alignment and the projected centers of mass of the spine.  
R-F: Risser-Ferguson Method of analysis  
Cobb: Cobb Method of analysis



**Spinal Biomechanics Compared to Normal**

| Global Analysis                   | Normal Values | Patient Values | Difference From Normal |
|-----------------------------------|---------------|----------------|------------------------|
| Risser-Ferguson Angle T11-L3 (L1) | 0.0°          | 20.7°          | 20.7°                  |
| Cobb Angle T11-L3                 | 0.0°          | 42.9°          | 42.9°                  |
| Translation at Apex T11-L3 (L1)   | 0.0 mm        | 10.6 mm        | 10.6 mm                |
| Translation T11-L3                | 0.0 mm        | -1.9 mm        | 1.9 mm                 |
| Translation T11-S1                | 0.0 mm        | 30.9 mm        | 30.9 mm                |
| HB Angle                          | 0.0°          | -8.1°          | 8.1°                   |

HB Angle = the angle formed by a line across the sacral base relative to horizontal.

Direction of measured displacements are indicated using the right-hand Cartesian coordinate system method in biomechanics. Consequently a "-" negative sign preceding a measured value indicates left translation for linear movements; and a "-" preceding angular measurements indicate relative segmental or global rotational movement to the left.

Mr. Bad Spine has a 1 curve scoliosis at T11-L3 with the apex on the left at L1. Using the Risser-Ferguson method of analysis, Mr. Bad Spine's scoliosis measures 20.7 degrees (moderate), and using the Cobb method of analysis measures 42.9 degrees (severe).

Transitional lumbar segment noted with sacralization. No acute bony abnormalities or osseus disease.



**Radiographic Impression Report**

**AP Modified Ferguson View  
(Sacral Base)**

**Name: Bad Spine**  
**Date of Birth: 8/7/1954**

**X-Ray was obtained: 6/29/2013**

**Date of Digitization: 6/29/2013**

Mr. Bad Spine's x-rays were analyzed utilizing the PostureRay® computerized X-ray digitizing system with impressions interpreted by Dr. Joe Ferrantelli. X-Ray digitization for spinal biomechanics has been shown to be valid when compared to standard hand drawn methods. The patient's findings were then compared to established normals at each level and then globally. The X-Ray mensuration method used in analyzing this patient have been studied for reliability and validity and these results are as follows:

**Spinal Biomechanics Compared to Normal**

| Global Analysis           | Normal Values | Patient Values   | Difference From Normal |
|---------------------------|---------------|------------------|------------------------|
| Femur Unleveling*         | 0 mm          | right<br>2.8 mm  | 2.8 mm                 |
| Sacral Base Unleveling*   | 0 mm          | left<br>10.5 mm  | 10.5 mm                |
| Pubic Symphysis to S2     | 0 mm          | right<br>-3.0 mm | 3.0 mm                 |
| HB Angle                  | 0°            | -3.4°            | 3.4°                   |
| LS Angle T12-L5 (L2 apex) | 90°           | -89.1°           | 0.9°                   |
| LD Angle T12-L5           | 0°            | 8.4°             | 8.4°                   |
| Translation T12-S1        | 0 mm          | 5.6 mm           | 5.6 mm                 |

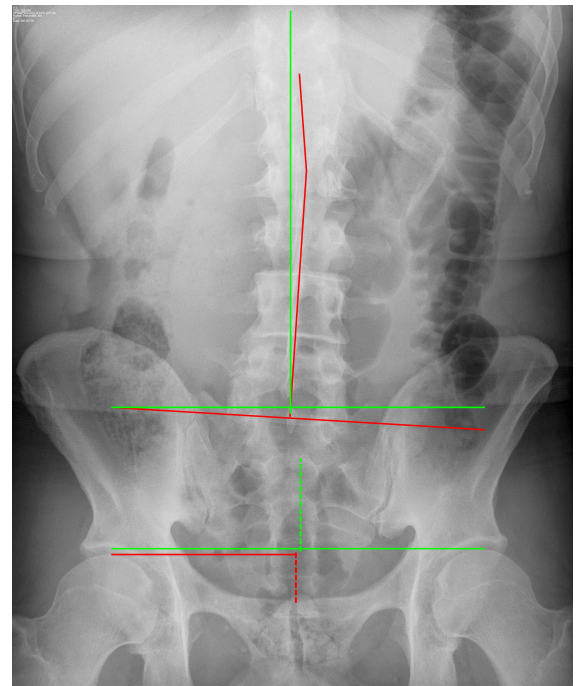
\* Accounting for magnification  
HB Angle = the angle formed by a line across the sacral base relative to horizontal.  
LS Angle = Lumbo-sacral angle  
LD Angle = Lumbar-Dorsal angle

**Impressions and Assessment**

As noted above in the table, the left side of the sacrum is deficient by 14.1mm accounting for magnification, it measures 10.5mm. The Femur offset is 3.7mm short on the right side which approximates 2.8mm, when accounting for magnification. As for the Pubic Symphysis offset to S2, it measures -3.0mm to the right.

There are sufficient visible vertebrae to measure that Mr. Bad Spine's upper lumbar spine is translated (listed) from plumb by 5.6 mm to the left. The patient has a mid lumbar curve of 8.4 degrees. The patient's sacral base is offset and inferior on the left.

This is an exam with a 12mm lift on the left - full orthotic.



**Right** **Left**

This green line represents normal spinal position.

This red line represents the patient's alignment and the projected centers of mass of the spine.



**Radiographic Impression Report**


**Other View - PA Back Posture**

Name: **Bad Spine**  
Date of Birth: **8/7/1954**

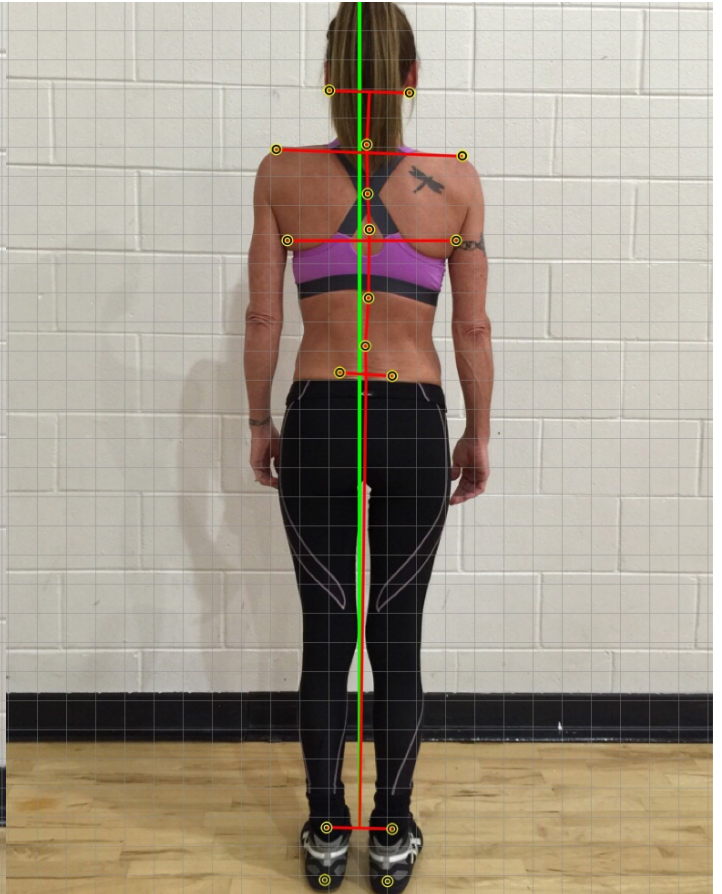
X-Ray was obtained: **6/29/2013**

Date of Digitization: **6/29/2013**

**AP Front Posture**



**PA Back Posture**



**AP Front Posture impressions:**

See PostureScreen Report on File

**PA Back Posture impressions:**

See PostureScreen report on file.



**Radiographic Impression Report**


**Other View - Right Lateral Posture**

Name: Bad Spine  
Date of Birth: 8/7/1954


X-Ray was obtained: 6/29/2013

Date of Digitization: 6/29/2013

**Left Lateral Posture**



**Right Lateral Posture**



**Left Lateral Posture impressions:**

See PostureScreen report on file.

**Right Lateral Posture impressions:**

See PostureScreen report on file.





**Radiographic Impression Report**

**Summary Impression**

**Name: Bad Spine**  
**Date of Birth: 8/7/1954**

**X-Ray was obtained: 6/29/2013**

**Date of Digitization: 6/29/2013**

Clinical correlation is made with the x-ray analysis at the following subluxated segments: C5/6/7 as well as mid thoracic spine and distal lumbar spine. Most notably the patient's history of complaints of cervicothoracic pain, headaches, cervical radiculopathy, and lumbar pain. Overall, the x-ray analysis findings do correlate with our clinical findings. This is causing neurological damage to the patient's spinal cord and instability to the osseous structures of their vertebral column. Left untreated this condition will worsen causing permanent aberrant spinal biomechanical and neurological degenerative changes in the spine.

I also suspect we may need correlation to MRI should no steady progress be achieved.

The patient's scoliosis can be stabilized with conservative methods and SpineCor bracing, as the patient has already consulted a surgeon, and at this time does not wish to undergo surgical intervention. Left untreated this condition will worsen causing permanent aberrant spinal biomechanical and neurological degenerative changes in the spine.